

# Probiotic supplementation as an alternative to antibiotics in broiler chickens

Grzegorz Tomczyk<sup>1</sup>, Jowita Samanta Niczyporuk<sup>1</sup>✉, Wojciech Kozdruń<sup>1</sup>, Anna Sawicka-Durkalec<sup>1</sup>, Łukasz Bocian<sup>2</sup>, Marcin Barabasz<sup>3</sup>, Marcin Michalski<sup>4</sup>

<sup>1</sup>Department of Poultry Diseases, <sup>2</sup>Department of Epidemiology and Risk Assessment, National Veterinary Research Institute, 24-100 Puławy, Poland

<sup>3</sup>Vetlines, 62-006 Janikowo, Poland

<sup>4</sup>Veterinary Support, 02-972 Warszawa, Poland  
 jowita.niczyporuk@piwet.pulawy.pl

Received: August 31, 2023

Accepted: February 15, 2024

## Abstract

**Introduction:** The broiler chicken digestive tract microbiome maintains the bird's immunity. Its composition has been shown to be important not only for the immune system but also for the gastrointestinal function and productivity of broiler chickens. If the microbiome is populated by supplementation with *Lactobacillus*, *Pediococcus* and *Saccharomyces* spp. – microorganisms with probiotic properties and alternatives to antibiotics – the immune system is stimulated. The use of probiotic supplements in the broiler production cycle can boost bird immunity and prevent adenovirus infection. The resilience of broiler chickens in different feeding schemes including supplementation with these microorganisms was assessed. **Material and Methods:** Four groups of Ross 308 chickens vaccinated on the standard scheme were investigated over 42 days. Group P received probiotics, prebiotics and vitamins; group AO received antibiotics; group P&AO received probiotics, prebiotics, vitamins and antibiotics; and the control group C received none of these. The birds' immunocompetence against common viral poultry pathogens and their immune response to an experimental challenge with a field strain of infectious bronchitis was evaluated by ELISA and production parameters were recorded. **Results:** Mortality was only observed in the control group and was 10%. All birds from the P, P&AO and AO groups responded to the challenge as would be expected of appropriately immunised chickens. **Conclusion:** The obtained results indicated that supplementation with synbiotic products and vitamins can enhance broiler chicken immunity and result in better production parameters.

**Keywords:** antibiotic, chicken immunity, IB challenge, probiotics.

## Introduction

The microbiome in the digestive tract of broiler chickens is changed by probiotic, prebiotic and vitamin supplementation and antibiotic usage. Its composition has been shown to be important in broiler chickens for the immune system and gastrointestinal tract's function as well as productivity (12). The microbiome is involved in the maintenance of immunity through its unique taxonomic composition. Strictly selected bacterial cultures given in appropriately defined individual schemes can have a significant positive effect on chicken immunity after becoming part of the microbiome (18). *Lactobacillus*, *Bifidobacterium*, *Pediococcus* and *Saccharomyces* are among bacteria which are antibiotic alternatives that can stimulate the immune system by strengthening the

intestinal barrier and immunity (3, 11, 12). Scientific research supported that supplementation with probiotic bacteria such as these produces health benefits in many species of animals and humans (14). Studies have shown that the use of probiotic cocktails supplemented three times in the broiler production cycle can have a beneficial effect on bird immunity and prevents adenovirus infection in poultry flocks by improving their immune status (18).

Studies were undertaken to assess the effect on the immune status of broiler chickens of probiotic, prebiotic and vitamin supplementation and antibiotic usage. The aim of the research was to determine that breeding systems without antibiotic use are possible, and therefore, most importantly, that it is effective and healthier to pursue traditional poultry farm breeding.

## Material and Methods

**Animals.** One-day-old ROSS 308 broiler chickens were hatched at the Malec Poultry Hatchery (Góra Kalwaria, Poland) and then delivered to the National Veterinary Research Institute (NVRI) in Puławy, Poland. All chickens were reared at the animal research facility of the NVRI.

**Study design, supplementation, and additives.** Four groups of 20 Ross 308 broiler chickens originating from young parent stock were housed for six weeks in BSL 3 animal facilities at the NVRI. Two replicates per supplementation were conducted, and therefore in total 160 birds were used for the studies. In the experiment, four different feeding schemes were evaluated. The first group was fed a normal diet, and neither antibiotic nor supplementation was used. This was the control group, C.

The second group was comprised of chickens maintained on a normal diet but also given supplementation with probiotics, prebiotics and vitamins. The probiotic strains were *Enterococcus faecium*, *Lactobacillus casei*, *Lactobacillus plantarum* and *Pediococcus acidilactici*, and they were all used at a final concentration of  $1.5 \times 10^{11}$  colony-forming units (CFU)/mL. Additionally, supplementation was provided of prebiotic fructooligosaccharides and the prebiotics inulin, maltodextrin and oligofructose at a final concentration of 250,000 mg, of vitamins B1 at 350 mg, B2 at 250 mg, B3 niacinamide at 2,000 mg, B5 panthenol at 1,200 mg, B6 at 320 mg, B12 at 1,000 µg, C at 30,000 mg, K3 at 300 mg, and folic acid at 3,000 mg, and of glucose, and silica. The broilers took these supplements in drinking water on the following scheme of three cycles: the first on the 2<sup>nd</sup>, 3<sup>rd</sup>, 4<sup>th</sup> and 5<sup>th</sup> days of life, the second on the 17<sup>th</sup>, 18<sup>th</sup> and 19<sup>th</sup> days of life, and the third on the 31<sup>st</sup>, 32<sup>nd</sup> and 33<sup>rd</sup> days of life. This was the pro- and prebiotic group, P.

The third group were the chickens fed the normal diet and antimicrobials. The drugs were enrofloxacin 500 mg/g (15 mg/kg body weight), given on the 1<sup>st</sup>, 2<sup>nd</sup>, 3<sup>rd</sup> and 4<sup>th</sup> days of life, fortamox (0.03 g/kg body weight) on the 14<sup>th</sup>, 15<sup>th</sup> and 16<sup>th</sup> days of life, and trimisulfazol on the 24<sup>th</sup>, 25<sup>th</sup> and 26<sup>th</sup> days of life in doses as follows: 10 mg/kg body weight, and 1.5 mL/L in drinking water, respectively. This group was referred to as the AO group.

The fourth group consisted of chickens provided with a normal diet with probiotic, prebiotic and vitamin supplementation, and also administered antibiotics. This group was designated P&AO.

The base diet was the normal diet for broiler chickens until six weeks old. The daily feed intake was 100 g/kg body weight. The concentration of live bacteria in the probiotic and prebiotic preparation was verified. The broiler chickens were examined on the 1<sup>st</sup>, 21<sup>st</sup> and 42<sup>nd</sup> days of life.

**Experiment design.** The average weekly gain for each group of chickens was monitored and birds were weighed individually on day 1, and then weekly until the end of the experiment on the 42<sup>nd</sup> day of life. The

experiment was conducted in duplicate. Chickens were provided *ad libitum* access to feed and water during the 42-day trial.

**Vaccination.** Chickens were vaccinated at the hatchery according to the standard vaccination schedule for broiler chickens. On day 14 after hatching, the birds were vaccinated with the infectious bursal disease Nobilis Gumboro D78 IBD vaccine (Intervet International, Boxmeer, the Netherlands) in accordance with the standard vaccination scheme.

**Challenge.** One week after vaccination, 21-day-old chickens from all groups were challenged with an infectious bronchitis virus (IBV) field strain designated G052/16 Ip CAS/SPF 2016-09-20 CT:15 IBV/Var2 with an  $EID_{50} = 10^{5.0}$ . The strain was obtained from the NVRI collection. The experimental challenge was conducted at the NVRI animal facilities in a high containment unit.

**Other studies conducted.** After the disease challenge model, the birds were observed clinically. The immune status as antibody levels, all parameters connected with the presence of pathogens, body mass index, health parameters and mortality rate were assessed in individual birds. Anatomopathological examinations of dead and euthanised birds were conducted.

**Sampling.** Samples were collected from each of the four experimental groups. Birds were euthanised by cervical dislocation after isoflurane administration in accordance with the protocol submitted to the local animal ethics committee. Anatomopathological examinations were conducted during which the heart, liver, spleen, gizzard, intestines, lungs, and kidneys were collected and changes in them were described.

**Serological testing by enzyme immunoassay.** Serum samples taken from one-day-old and three- and six-week-old chickens were tested for the presence of antibodies against specific viral antigens: chicken anaemia virus (CAV), avian orthoreovirus (ARV), infectious bursal disease virus (IBD), infectious bronchitis virus (IBV) and fowl adenovirus (FAdV). All samples were tested with ELISA immunoassays dedicated to these poultry pathogens in accordance with the manufacturers' instructions. The assays used were an IDEXX CAV Ab Test (IDEXX Laboratories, Westbrook, ME, USA); ID Screen Avian Reovirus Indirect, ID Screen IBD Indirect and ID Screen Infectious Bronchitis Indirect (all Innovative Diagnostics, Grabels, France); and FAdV Group 1 Antibody test (BioChek, Reeuwijk, the Netherlands). Sera from chickens were also tested for the presence of antibodies against the antigens *Mycoplasma gallisepticum* and *M. synoviae* with an IDEXX MG/MS Ab Test (IDEXX Laboratories).

**Anatomopathological examinations.** Changes in the internal organs were assessed according to the following scale: no visible changes; visible minor changes in the form of hyperaemia; medium-grade hyperaemia of the mucous membrane with minor petechiae observed; and strongly expressed hyperaemia of the mucous membrane, marked petechiae, and enlargement and swelling of internal organs.

**Microbiological identification.** Microbiological identification was performed using 5% horse blood agar, MacConkey agar, and brilliant green agar culture media (Condalab, Madrid, Spain). Bacterial colony identification was performed using the standard method for mass spectrum profile (MSP) identification with a matrix-assisted laser desorption/ionisation–time-of-flight Biotyper (Bruker Daltonics, Bremen, Germany).

**Statistical analysis.** Statistical analysis was carried out using the Mann–Whitney *U* test and, where possible, Student's *t*-test. The normality of distributions was tested with the Shapiro–Wilk test, and the homogeneity of variance with Levene's and the Brown–Forsythe tests. The relationships described were statistically demonstrated at the assumed significance level of  $\alpha = 0.05$ . Analyses were performed using Statistica version 13 (TIBCO Software, Palo Alto, CA, USA).

## Results

**Clinical signs observed.** The clinical signs observed in infected chickens included depression, ruffled feathers, coughing, and tracheal and respiratory lesions. The mortality rate in chickens from the control group vaccinated and infected with the IBV/Var2 G052/16 strain was 10% at 7 and 12 days post infection (dpi). No mortality was observed in chickens from the P, P&AO or AO groups. All birds from groups P, P&AO and AO responded as expected to pathogen contact following appropriate immunisation (Table 1).

**Anatomopathological examinations.** There were no macroscopic changes in the liver, while the kidneys were clearly enlarged and hyperaemic in the AO and P&AO groups. In these groups, no erosions or mucosal lesions were noted. No macroscopic changes were observed in other internal organs. In the P&AO and AO groups, inflammatory changes were observed in the duodenum, manifested by hyperaemia of the mucous membrane and oedema of the liver and kidney ranging in severity in 8 out of 10 birds in the AO group and in 6 out of 10 in the P&AO group. In all chickens, various degrees of change related to congestion of the mucous membrane of the small intestine were observed; these changes observed in the control group may have indicated the influence of the stress factor. In the AO and P&AO groups, significantly more marked inflammatory changes were observed. These changes could have been caused by antibiotics. In two chickens from the control group characteristic inflammatory changes in the digestive tract have been observed. In the control group, the birds were smaller, with lower production parameters, and lesions in the trachea and respiratory system were noted until the 7<sup>th</sup> day after challenge. Data are presented in Table 2.

**Serological studies.** Serological examinations were conducted on serum samples obtained from all 20 birds per group. The level of maternal antibodies was determined to evaluate the parental flock vaccination programme.

The vaccination of the experimental birds and their immunity were also assessed on the basis of the obtained results. The possibility of the occurrence of health problems was determined by comparing the chickens across groups. Mean antibody titres (arithmetic and geometric) and the coefficient of variation were calculated and documented. The results obtained for antibodies against infectious anaemia virus suggested that the chickens maintained maternal antibodies up to two weeks of age. The highest levels were found in the P and P&AO groups.

The results of tests for antibodies against infectious bursal disease virus demonstrated levels of maternal antibodies in one-day-old chickens of all groups. No clinical symptoms of IBD infection were observed in the examined birds however still a few positive serological results concerning characteristic IBD antibodies presence were recorded.

Noteworthy is the high average titre and high coefficient of variation (52.2%) in the six-week-old birds from the P&AO and AO groups. However, the remaining birds had satisfactory levels of antibodies and the applied immunoprophylactic programmes appeared to be effective.

A high coefficient of variation (83.0%) applied to the anti-infectious bronchitis virus antibody titres in the P group in the six-week-old chickens. An even higher coefficient of variation was found in one-day-old chickens in the C group, where neither probiotics nor antibiotic were supplemented or administered, and this was 85.3%. Production of the antibodies in the P&AO group was induced by contact with the field virus.

The presence of specific antibodies to avian reoviruses was also reported, which play a major role in protecting chickens against reovirus infection. There was an even level of maternal antibodies in one-day-old chickens of all tested groups, where the coefficient of variation of 21.5% in the P&AO group compared to one of 29.5% in the AO group.

The flocks were also tested for mycoplasma infection. The presence of specific antibodies to *M. synoviae* and *M. gallisepticum* was not correlated with the degree of immunity. Hence, the antibodies did not protect against infection, clinical signs or transmission. No specific antibodies against *M. gallisepticum* were found in any of the chicken groups tested. In contrast, the presence of *M. synoviae* antibodies was found in group C in one-day old chickens of this age in seven tested samples. Antibodies to *M. synoviae* were also found in one sample from group P and one from P&AO, as well as in seven samples from the AO group. In three-week-old and six-week-old chickens, no antibodies were found. Equal maternal antibody titres to poultry adenoviruses were also noted across the groups in one-day-old chickens.

The obtained results suggested that chickens from the P and P&AO groups showed a stronger vaccination protection index against pathogens commonly existing in poultry flocks, which was also closely correlated with a higher rate of weight gain in the P&AO group.

**Table 1.** Clinical changes and mortality rates in broiler chicken groups challenged with infectious bronchitis

Day/s post challenge	Prevalence of clinical manifestations/deaths			
	Group P (n = 20)	Group AO (n = 20)	Group P&AO (n = 20)	Group C (n = 20)
1	0/0	0/0	0/0	0/0
2	0/0	2/0	1/0	0/0
3	11/0	10/0	12/0	14/0
4	10/0	9/0	12/0	14/0
5	7/0	5/0	7/0	8/0
6	1/0	0/0	0/0	2/0
7	0/0	0/0	0/0	0/1
8	0/0	0/0	0/0	0/0
9	0/0	0/0	0/0	0/0
10	0/0	0/0	0/0	0/0
11	0/0	0/0	0/0	0/0
12	0/0	0/0	0/0	0/1
13	0/0	0/0	0/0	0/0
14	0/0	0/0	0/0	0/0
21	0/0	0/0	0/0	0/0
Mortality %	0	0	0	10

Group P – supplemented with the probiotics *Enterococcus faecium*, *Lactobacillus casei*, *Lactobacillus plantarum* and *Pediococcus acidilactici*; prebiotic fructooligosaccharides and the prebiotics inulin, maltodextrin and oligofructose; vitamins B1, B2, B3, B5, B6, B12, C, K3 and folic acid, and glucose and silica; Group AO – treated with the antibiotics enrofloxacin, fortamox and trimisulfasol; Group P&AO – supplemented with probiotics, prebiotics and vitamins and treated with antibiotics; Group C – not supplemented nor treated with antibiotics

**Table 2.** Results of necropsy of four broiler chicken groups challenged with infectious bronchitis

Group	n	gizzard	intestines	liver	spleen	BF	kidneys	lungs
P	10	0	**2/10	0	0	0	0	**1
AO	10	6/10	***3/10 ****5/10	****8/10	0	0	****5/10	**2
P&AO	10	0	***2/10 ****4/10	****6/0	0	0	****6/10	**2
C	10	0	**2/10	0	0	0	0	**2

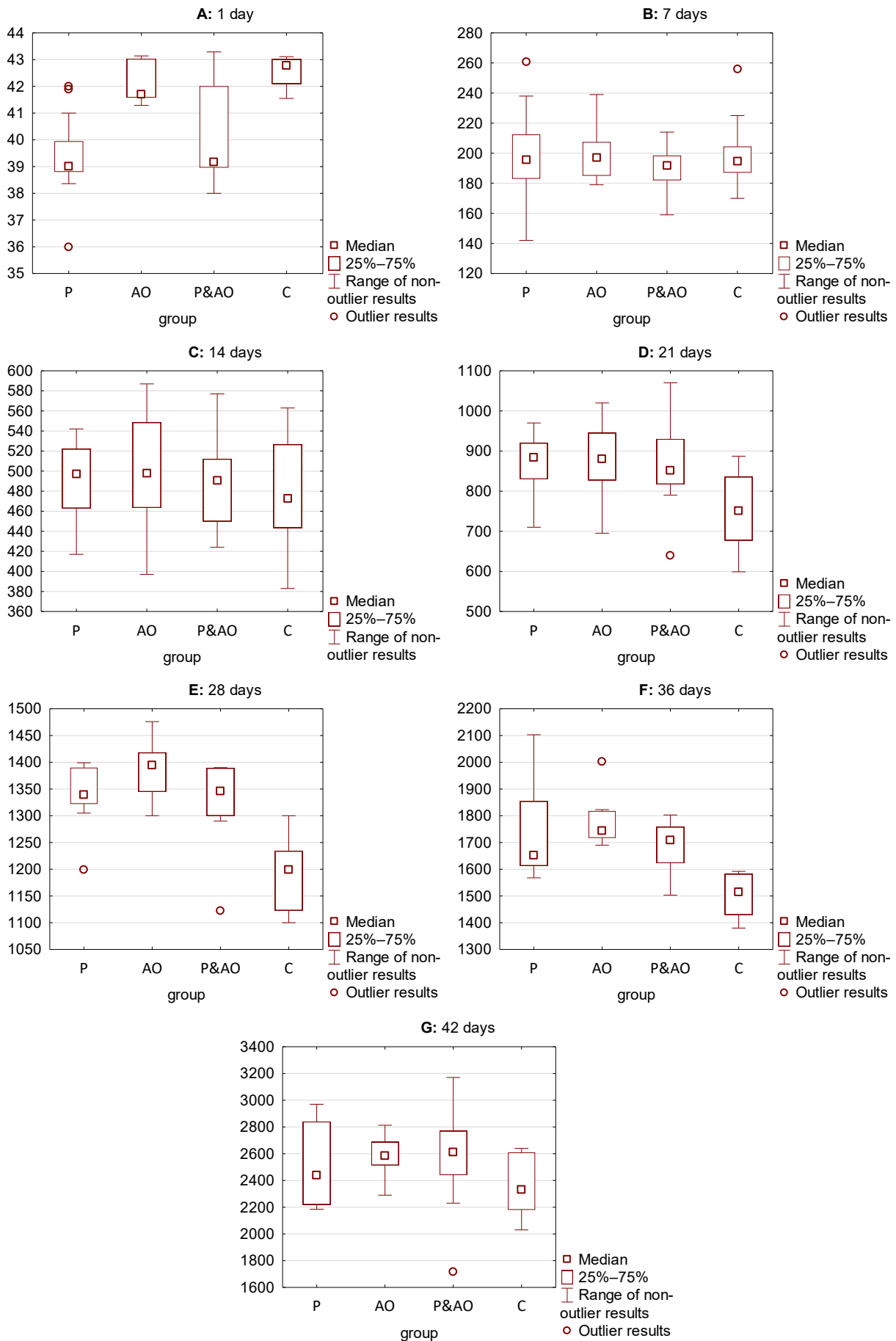
BF – Bursa of Fabricius ; Group P – supplemented with the probiotics *Enterococcus faecium*, *Lactobacillus casei*, *Lactobacillus plantarum* and *Pediococcus acidilactici*; prebiotic fructooligosaccharides and the prebiotics inulin, maltodextrin and oligofructose; vitamins B1, B2, B3, B5, B6, B12, C, K3 and folic acid, and glucose and silica; Group AO – treated with the antibiotics enrofloxacin, fortamox and trimisulfasol; Group P&AO – supplemented with probiotics, prebiotics and vitamins and treated with the antibiotics enrofloxacin, fortamox and trimisulfasol; Group C – not supplemented nor treated with antibiotics

\* – no visible changes in internal organs; \*\* – visible minor changes in the form of hyperaemia; \*\*\* – medium-grade hyperaemia of the mucous membrane and minor petechiae; \*\*\*\* – severe hyperaemia of the mucous membrane, marked petechiae, and enlargement and swelling of internal organs

**Microbiological studies.** *Escherichia coli* and *Enterococcus faecium* were detected in microbiological studies carried out on the livers, yolk sacs and hearts collected from one-day-old chickens from the P group. *Escherichia coli* growth was abundant in samples of the yolk sacs of P group birds. Growth of *Escherichia coli* and *Enterococcus hirae* was found in liver and heart samples collected from three-week-old chickens in this group. *Escherichia coli*, *Streptococcus alactolyticus* and *Aerococcus viridans* were detected in liver samples from the six-week group of chickens treated with the antibiotics (the AO group), and internal organs collected from one-day-old chickens in this group showed the presence of *Enterococcus casseliflavus*, *Enterococcus hirae*, *Enterococcus faecium* and *Escherichia coli*, while no increase in bacterial flora was found in the heart samples. The presence of *Enterococcus hirae* and *faecium* was also confirmed in the yolk-sac samples in P group. *Streptococcus alactolyticus* and *Staphylococcus*

*cohnii* were isolated in samples from the livers of three-week-old birds, and the former along with *Staphylococcus xylosus* was found in heart samples. From liver samples from six-week-old chickens, *Proteus mirabilis* was isolated, and *Escherichia fergusonii* and *Candida rugosa* were detected in heart samples from AO group.

In the control group of chickens after one day of life, *Corynebacterium stationis*, *Streptococcus alactolyticus* and *Enterococcus casseliflavus* were detected in the liver. In the heart, *Escherichia coli* and *Streptococcus alactolyticus* were confirmed. In the third week, bacterial growth of *Escherichia coli* and *Enterococcus hirae* was found only in liver samples. In the heart samples collected from six-week-old chickens, besides the bacteria species *Enterococcus casseliflavus*, the species *durans* was also found. In liver samples, *Enterococcus gallinarum* and *Acinetobacter twoffii* were confirmed.



**Fig. 1 A-G.** Statistical analysis of body weight in chickens from control and experimental groups. Group P – supplemented with the probiotics *Enterococcus faecium*, *Lactobacillus casei*, *Lactobacillus plantarum* and *Pediococcus acidilactici*; prebiotic fructooligosaccharides and the prebiotics inulin, maltodextrin and oligofructose; vitamins B1, B2, B3, B5, B6, B12, C, K3 and folic acid, and glucose and silica; Group AO – treated with the antibiotics enrofloxacin, fortamox and trimisulfazol; Group P&AO – supplemented with probiotics, prebiotics and vitamins and treated with antibiotics; Group C – not supplemented nor treated with antibiotics. Statistical analysis was carried out using the Mann–Whitney *U* test and where possible, Student’s *t*-test. The normality of distributions was tested with the Shapiro–Wilk test, and the homogeneity of variance with Levene’s and the Brown–Forsythe tests. The relationships described a level of  $\alpha = 0.05$

In one-day-old chickens supplemented with probiotics, prebiotics, vitamins and antibiotics – the P&AO group – the growth of bacteria was found only in liver samples and the species were *Enterococcus hirae* and *faecium* and *Escherichia coli*. In liver samples taken from six-week-old chickens, the following bacterial species were found: *Staphylococcus hominis* and *cohnii*, *Streptococcus alactolyticus*, *Corynebacterium* spp., and *Escherichia coli*. Only *Escherichia coli* was identified in heart samples in six-week-old chickens.

**Statistical analysis.** The average body weights of chickens at 7, 14, 21, 28, 36 and 42 days of life were analysed by the Mann–Whitney *U*, Shapiro–Wilk, Levene’s, Brown–Forsythe and Student’s *t*-test. Statistically significant differences were noted for the individual groups P, AO, and P&AO when compared with C, with a P-value <0.0500 being considered to be significant. The reduction of weight gain was significant from 28 dpi until the end of the experiment ( $P < 0.0500$ ) (Fig. 1). In the comparison of group P with group C, the day 1 P-value was 0.0001, the day 21 P-value was 0.0001, the day 28 comparison produced 0.0007 and for day 36 it was 0.0006. This analysis was by Mann–Whitney *U* test (continuity corrected). The condition takes into account group AO and group P&AO. When the AO group average body weights were compared with those of group C, a P-value of 0.0002 emerged for day 21, one of 0.0002 was also calculated for day 28, the value was unchanged for day 36, and using Student’s *t*-test for the day 42 comparison the P-value was 0.0338. Except the noted exception on day 42, the P-values were found in a Mann–Whitney *U* test (continuity corrected). The condition takes into account group P and group P&AO. The P&AO group was also analysed against group C. Body weights measured on day 1 were statistically different, shown by a P-value of 0.0002; those on day 21 also were and the resulting P-value was 0.0011, weights on day 28 gave a P-value of 0.0022 and those on day 36 returned 0.0028. As in other groups’ analyses, a Mann–Whitney *U* test (continuity corrected) was applied. The condition takes into account group P and group AO.

Based on the Shapiro–Wilk test, the hypothesis of normal distribution should be rejected in the case of day 1 body weights in groups AO, P&AO and C; day 28 body weights in group P&AO; and day 36 values in group AO.

## Discussion

In the conducted studies it was seen that probiotics, prebiotics and vitamins added on appropriate schedules during the entire 42-day production cycle of broiler chickens significantly contributed not only to strengthening the immune status of chickens, which reduces viral infections, but also to eliminating the need to administer antibiotics to the experimental broiler chicken groups. The role of group C was as a benchmark against which to determine the impact of synbiotic components and antibiotics as administered to groups P,

P&AO and AO. The difference in body weight gain between the control group and the group of chickens receiving probiotics, prebiotics, vitamins and antibiotics showed statistically significant values.

Many authors suggested that the immunostimulant activity of probiotic cocktails is correlated with their ability to induce phagocytosis and secretion of immunoglobulin A, improving T cells, enhancing Th1 responses, and reducing Th2 response (1, 6, 9, 15). The mortality rate in the present study was indicated as 0% in the experimental groups and 10% only in the control group of chickens at 7 and 12 dpi; the immunological status of the control birds was lower than that in groups P, P&AO and AO. The immunomodulatory capacity of bacteria found in the probiotic cocktails with which the chickens were supplemented may suggest that it is enhanced by the synbiotic mix of prebiotics and probiotics and by the vitamins. Probiotics and prebiotics have been shown to prevent the development of colon cancer in animals, and to reduce the activity of enzymes known to produce genotoxic compounds that act as tumour initiators (9, 17). In addition to playing an important role in barrier defence (2), probiotics are put to growing use in modulating the immunity of the intestinal mucosa, and may modulate the activity of many cells in the immune system, including natural killers, dendritic cells, macrophages, epithelial cells, and granulocytes as well as the adaptive system lymphocytes Th1, Th2, Th17, Treg, Tc, and B (10, 21).

Lactic acid bacteria such as *Lactobacillus* and *Bifidobacterium* can have a positive impact on health (2, 20). Supplementation of farm animal feed with probiotic substances makes it possible to reduce antibiotic overuse in animal agriculture and thereby implement a key strategy in the fight against the spread of bacterial antibiotic resistance, which is currently a matter of importance in the European Union and an area in which it has enacted laws (19). Probiotic feeding resulted in a lower feed conversion ratio and induced the highest level of immune response, suggesting high economic benefits in broiler farming. As some authors suggested, probiotic addition to feed may be a promotor of intestinal health and may contribute to improved feed efficiency during birds’ growth periods (8). The efficacy of *Lactobacillus johnsonii* in control of *Escherichia coli* O78:K80 and *Clostridium perfringens* in poultry was evaluated and strain FI9785 of the probiotic was successful in suppressing the development of *Clostridium perfringens* infections (16). However, genetic characterisation of candidate probiotic strains is essential in order to confirm their safety and ensure that they contain no virulence or antibiotic resistance genes (5, 6).

Prebiotics are additives that can stimulate the commensal flora and enhance the beneficial effects of probiotics within the host. They are mostly indigestible oligosaccharides, as indicated by Patel and Goyal (19) as well as in the studies previously referred to. Prebiotics are often used as feed additives in broiler diets (7), where they have been shown to improve intestinal health and

immune response, and can help to prevent colonisation by reducing adhesion by pathogenic bacteria (7). Molecular studies on the presence of immunosuppressor viruses such as adenoviruses were performed and confirmed the presence of genetic material of FAdV type/species 1/A and 5/B in broiler chicken flocks on control farms on which neither antibiotics nor probiotics, prebiotics and vitamins were supplemented (18).

The useful functions of probiotics are many and include modification of the host metabolism, immunostimulation, activation of anti-inflammatory processes, exclusion and counteraction of pathogens in the gastrointestinal tract, reduction of bacterial contamination, improvement of nutrient absorption (6), and reduction of risk to human health (2, 10). These actions can mostly be attributed to the ability of most probiotic products to balance and maintain the gut microflora in poultry (6). The main functions of the intestinal microflora are metabolic functions, which help restore energy and make it possible for the gut to absorb nutrients, as well as the exertion of important trophic effects on the intestinal epithelium and function of the immune system together with protection of the colonised host against invasion of foreign microorganisms. Imbalance of the gut microflora can also be an important factor in some diseases, including multi-organ failure, colon cancer and inflammatory bowel diseases (10, 16). Probiotics and prebiotics are known to play a role in the prevention or treatment of certain diseases, notably those which cause diarrhoea (9). Besides strain F19785 of *Lactobacillus johnsonii*, strain La1 of this species has been studied, and *Lactobacillus rhamnosus* GG, *Lactobacillus casei* Shirota, *Bifidobacterium animalis* BB-12, *Bifidobacterium lactis* DR10 and *Saccharomyces cerevisiae boulardii* are other probiotic cultures which have deserved extensive investigation because of their immunomodulatory properties (9). These probiotics can enhance non-specific cellular immune responses characterised by the activation of macrophages, natural killer cells, and antigen-specific cytotoxic T cells (2).

In studies conducted *in vitro*, the immunostimulatory effect of two *Bacillus* species was confirmed, *Bacillus subtilis* FPTB13 being more effective than *Bacillus amyloliquefaciens* FPTB16 (13). Selected *Lactobacillus* strains showed different immunomodulating effects in laying hens and broiler chickens. Specific and non-specific immune responses, both humoral and cellular, have also been studied when induced by *Lactobacillus reuteri* DSM 16350, *Enterococcus faecium* DSM 16211, *Bifidobacterium animalis* DSM 16284, *Pediococcus acidilactici* DSM 16210 and *Lactobacillus salivarius* DSM 16351 (20). Cell proliferation, entry, and survival of *Salmonella* in intestinal and spleen leukocytes, and immunoglobulin level specifications were investigated. Research was also conducted on changing different feeding modes and doses of probiotics at doses which would be implementable in the field and when given at intervals which would be practical on farms. Probiotics and prebiotics can have the influence to intestinal

microbiota and immune system taking in to the reduce colonisation by pathogenic bacteria in strictly specific conditions. The process of the inhibition of pathogens is done by the intestinal microbiota as bacterial antagonism or barrier effect and competitive exclusion by which the intestinal bacteria inhibit pathogenic bacteria including competition for the colonisation of ecological niches inside the intestine and prevent the disease (20). Lactic acid bacteria can also increase resistance to some diseases and can be enriched in the intestinal tract by feeding carbohydrates (3, 15, 20–21).

Data from other authors suggest that probiotics can significantly change the intestinal microflora, stimulating the proper growth and development of animals (8). Both antibiotics and probiotics affect the growth of chickens; however, only probiotics are beneficial to the health of the consumer and do not contribute to the emergence of drug resistance (5). These findings were also confirmed in the present studies.

The presented study shows that the observed hepatomegalous changes in the P&AO and AO groups were not large enough to threaten the animals' lives. However, their occurrence in the P&AO and AO groups must not be overlooked. Antibiotics may cause side effects in chickens. Antimicrobials can cause inflammation of the gastrointestinal tract of varying severity in different parts of the intestine, and can also cause liver and kidney function disorders. Antimicrobial activities need not only be recruited from antimicrobials themselves: probiotic bacteria have also been shown to produce molecules with antimicrobial activities, such as bacteriocins, that target specific pathogens, or even inhibit the adhesion of pathogens or the production of pathogenic toxins (4). Unfortunately for proponents of the replacement of antibiotics by probiotics, antibiotics achieve better weight gain in broiler chickens.

## Conclusion

Probiotic substances have an influence on bird immunity with their activation of local cell-mediated immunity against pathogens. Probiotic supplementation as indicated can help to reduce antimicrobial use and therefore lessen antibiotic residue in food animals and stop the spread of antibiotic resistance. The results of serological tests indicated that supplementation of probiotics, prebiotics and vitamins in broiler chickens may have a positive effect on production parameters.

**Conflict of Interests Statement:** The authors declare that there is no conflict of interests regarding the publication of this article.

**Financial Disclosure Statement:** This research was part of the EU-China HealthyLivestock project. The authors wish to acknowledge that HealthyLivestock is funded by the European Union Horizon 2020 research and innovation programme under grant agreement

number 773436. The European Commission's support for the production of this publication does not constitute an endorsement of the contents, which reflect the views only of the authors, and the Commission cannot be held responsible for any use which may be made of the information contained therein.

**Animal Rights Statement:** The procedures followed were in accordance with the ethical standards of the responsible committee and institutional and national law. These studies were conducted in accordance with the guidelines of the Local Ethics Committee for Animal Experiments in Lublin and approved under Resolution No. 43/2019 of July 1, 2019. The Committee has approved all the procedures in this study in accordance with the Polish laws and WOAHP animal welfare standards for animal care and use in research and education.

**Acknowledgements:** We would like to thank Wiesława Deska and Karolina Piekarska for preparing samples for testing, and Prof. Katarzyna Domańska-Blicharz for providing a field IBV strain for the experimental trials on chickens.

## References

1. Angelakis E., Merhej V., Raoult D.: Related actions of probiotics and antibiotics on gut microbiota and weight modification. *Lancet* 2013, 13, 889–899, doi: 10.1016/S1473-3099(13)70179-8.
2. Ashraf N.P., Shah N.P.: Immune system stimulation by probiotic microorganisms. *Crit Rev Food Sci Nutr* 2014, 54, 938–956, doi: 10.1080/10408398.2011.619671.
3. Awais M.M., Jamal M.A., Akhtar M., Hameed M.R., Anwar M.I., Ullah M.I.: Immunomodulatory and ameliorative effects of *Lactobacillus* and *Saccharomyces* based probiotics on pathological effects of eimeriasis in broilers. *Microb Pathog* 2019, 126, 101–108, doi: 10.1016/j.micpath.2018.10.038.
4. Caly D.L., D'Inca R., Auclair E., Drider D.F.: Alternatives to Antibiotics to Prevent Necrotic Enteritis in Broiler Chickens: A Microbiologist's Perspective. *Front Microbiol* 2015, 6, 1336, doi: 10.3389/fmicb.2015.01336.
5. Dibner J.J., Richards J.D.: Antibiotic growth promoters in agriculture: History and mode of action. *Poult Sci* 2005, 84, 634–643, doi: 10.1093/ps/84.4.634.
6. Edens F.W.: An alternative for antibiotic use in poultry: probiotics. *Braz J Poult Sci* 2003, 5, 75–97, doi: 10.1590/S1516-635X2003000200001.
7. Fowler J., Kakani R., Haq A., Byrd J.A., Bailey C.A.: Growth promoting effects of prebiotic yeast cell wall products in starter broilers under an immune stress and *Clostridium perfringens* challenge. *J Appl Poult Res* 2015, 24, 66–72, doi: 10.3382/japr/pfv010.
8. Gao P., Ma C., Sun Z., Wang L., Huang S., Su X., Xu J., Zhang H.: Feed-additive probiotics accelerate yet antibiotics delay intestinal microbiota maturation in broiler chicken. *Microbiome* 2017, 5, 91.
9. Guarner F., Malagelada J.R.: Gut flora in health and disease. *Lancet* 2003, 361, 512–519, doi: 10.1016/S0140-6736(03)12489-0.
10. Hardy H., Harris J., Lyon E., Beal J., Foey A.D.: Probiotics, prebiotics and immunomodulation of gut mucosal defences: homeostasis and immunopathology. *Nutrients* 2013, 5, 1869–1912, doi: 10.3390/nu5061869.
11. Hemaiswarya S., Raja R., Ravikumar R., Carvalho I.S.: Mechanism of action of probiotics. *Br Arch Biol Tech* 2013, 56, 113–119, doi: 10.1590/S1516-89132013000100015.
12. Higgins P., Higgins S.E., Vicente J.L., Wolfenden A.D., Tellez G., Hargis B.M.: Temporal effects of lactic acid bacteria probiotic culture on *Salmonella* in neonatal broilers. *Poultry Sci* 2007, 86, 1662–1666.
13. Kamilya A., Baruah T., Sangma T., Chowdhury S., Pal P.: Inactivated probiotic bacteria stimulate cellular immune responses of catla, *Catla catla* (Hamilton) *in vitro*. *Probiotics Antimicrob Proteins* 2015, 7, 101–106, doi: 10.1007/s12602-015-9191-9.
14. Kechagia D., Basoulis D., Konstantopoulou S., Dimitriadi D., Gyftopoulou K., Skarmoutsou N., Fakiri E.M.: Health benefits of probiotics: a review. *ISRN Nutrition* 2013, 2013, 481651, doi: 10.5402/2013/481651.
15. Koenen M.E., Kramer J., Hulst R.V., Heres L., Jeurissen S.H.M., Boersma W.J.A.: Immunomodulation by probiotic lactobacilli in layer- and meat-type chickens. *Br Poultry Sci* 2004, 45, 355–366, doi: 10.1080/00071660410001730851.
16. La Ragione R.M., Narbad A., Gasson M.J., Woodward M.J.: *In vivo* characterization of *Lactobacillus johnsonii* F19785 for use as a defined competitive exclusion agent against bacterial pathogens in poultry. *Lett Appl Microbiol* 2004, 38, 197–205, doi: 10.1111/j.1472-765X.2004.01474.x.
17. Mountzouris K.C., Tsitsirikos P., Palamidi I., Arvaniti A., Mohnl M., Schatzmayr G., Fegeros K.: Effects of probiotic inclusion levels in broiler nutrition on growth performance, nutrient digestibility, plasma immunoglobulins, and cecal microflora composition. *Poultry Sci* 2010, 89, 58–67, doi: 10.3382/ps.2009-00308.
18. Niczyporuk J.S., Kozdruń W., Tomczyk G., Piekarska K., Barabasz M.: Molecular characteristics of fowl adenovirus strains detected in broiler chickens that did not receive diet supplements to improve immunity. *J Vet Res* 2024. In print.
19. Patel S., Goyal A.: The current trends and future perspectives of prebiotics research: a review. *3 Biotech* 2012, 2, 115–125, doi: 10.1007/s13205-012-0044-x.
20. Patterson J.A., Burkholder K.M.: Application of prebiotics and probiotics in poultry production. *Poultry Sci* 2003, 82, 627–631, doi: 10.1093/ps/82.4.627.
21. Pourakbari M.R., Seidavi A., Asadpour L., Martinez A.: Probiotic level effects on growth performance, carcass traits, blood parameters, cecal microbiota, and immune response of broilers. *Ann Braz Acad Sci* 2016, 2, 1011–1021, doi: 10.1590/0001-3765201620150071.